

ONLINE FIRST

Successful and Rapid Treatment of Blue and Green Tattoo Pigment With a Novel Picosecond Laser

Jeremy A. Brauer, MD; Kavitha K. Reddy, MD; Robert Anolik, MD; Elliot T. Weiss, MD; Julie K. Karen, MD; Elizabeth K. Hale, MD; Lori A. Brightman, MD; Leonard Bernstein, MD; Roy G. Geronemus, MD

Background: While the understanding and technology of laser tattoo removal has advanced much over the last 5 decades, treatments and results remain far from perfect. With currently available devices, treatment courses are often painful and prolonged with mixed results. We describe the successful and rapid treatment of 12 tattoos containing blue and/or green pigment with a novel, picosecond, 755-nm alexandrite laser.

Observations: All previously untreated multicolored tattoos as well as tattoos recalcitrant to treatment demonstrated at least 75% clearance of blue and green pig-

ment after 1 or 2 treatments with a novel, picosecond, 755-nm alexandrite laser. More than two-thirds of these tattoos approached closer to 100% clearance.

Conclusions: While additional future studies are needed, we believe that this new technology is more effective in targeting blue and green pigment, resulting in expedited clearance with less collateral injury to surrounding tissue.

Arch Dermatol.

Published online May 21, 2012.

doi:10.1001/archdermatol.2012.901

WITH ADVANCES IN the understanding, theory, and technology of lasers and related energy devices over the last 45 years, the field has also been witness to the evolution of tattoo removal.¹ Tattoo removal has graduated from the days of nonselective ablation with the carbon dioxide and argon-ion continuous-wave lasers to the present selective photothermolysis with quality-switched (QS) lasers.²⁻⁶ Adverse effects such as scarring and dyspigmentation have been greatly reduced because water is no longer the target chromophore.

Furthermore, the generally smaller tattoo pigments possess shorter thermal relaxation times, requiring treatment with lasers possessing even shorter pulse durations. At present, currently available QS lasers reliably release high-powered pulses in the range of nanoseconds.⁷ This fast heating causes rapid expansion, fragmentation, and resultant formation of acoustic waves, along with photothermal effects, that ultimately destroy the tattoo particles.⁸⁻¹⁰ However, while the advances in laser science are certainly impressive, the art of tattoo removal is still far from perfect.

Author Affiliations: Laser & Skin Surgery Center of New York, New York (Drs Brauer, Reddy, Anolik, Weiss, Karen, Hale, Brightman, Bernstein, and Geronemus); Department of Dermatology, Weill Cornell Medical Center, New York, New York (Drs Weiss and Bernstein); and The Ronald O. Perleman Department of Dermatology, New York University School of Medicine, New York (Drs Karen, Hale, and Geronemus).

REPORT OF CASES

We describe a series of 10 patients with 12 tattoos containing blue and/or green pigment that were either previously untreated and multicolored or recalcitrant to previous treatment. *Recalcitrant tattoos* were defined as those with clinically apparent pigment after at least 10 previous treatments. One patient had 2 untreated multicolored tattoos, and 1 patient had 2 recalcitrant tattoos. The average age of the patients was 31.5 years (age range, 23-39 years). Fitzpatrick skin types of these patients ranged from II to IV. Most of the tattoos were located on the upper back or shoulder, followed by the leg or thigh, abdomen, and arm. Additional colors reported in the 10 multicolored tattoos included black, white, yellow, red, orange, and purple. The average age of the untreated tattoos was 9.5 years (range, 2-20 years). The 1 patient's 2 recalcitrant tattoos were of 13 and 15 years' duration (**Table**).

Of the 10 multicolored tattoos, 3 consisted of green pigment only; 6 had blue and green pigment; and 1 tattoo was described by the patient as having "turquoise" pigment. This particular patient

Table. Demographic and Tattoo Information

Patient No./Age, y	Tattoo No.	Skin Type (I-VI)	Tattoo Age, y	Tattoo Location	Tattoo Colors	Miscellaneous
1/39	1	II	18	Upper back	Blue, green, yellow, black, white	Patient-reported "turquoise"
2/39	2	III	20	Upper back	Blue, green, yellow, black, red	No comment
3/23	3	IV	3.5	Shoulder	Blue, green, orange, black, red, purple	No comment
4/35	4	III	15	Upper arm	Green, black, red	No comment
5/28	5	III	10	Abdomen	Blue, green, black, red	No comment
6/38	6	III	10	Leg	Blue, green, yellow, red, purple, black, orange	No comment
7/33	7	IV	2	Upper back	Blue, green, yellow, red, black	No comment
	8	IV	7	Thigh	Green, pink, black	No comment
8/23	9	IV	2.5	Neck	Blue, green, black, yellow	No comment
9/25	10	III	7	Leg	Green, black, yellow, red	No comment
10/30	11	III	15	Abdomen	Blue, green, black, purple	Patient-reported "turquoise"
	12	III	13	Upper back	Green, black, orange	No comment

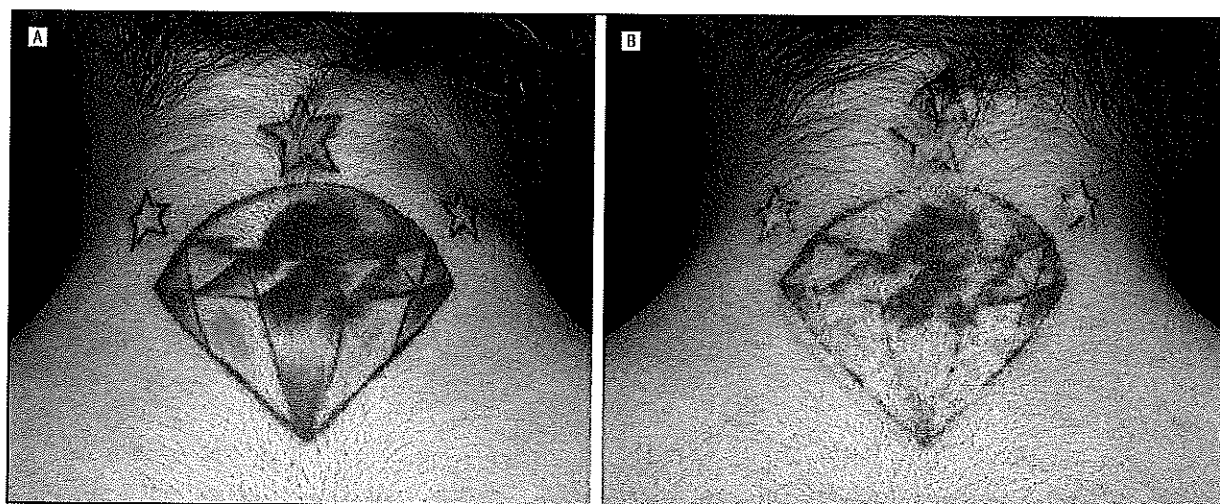


Figure 1. Previously untreated multicolored tattoo, including green and blue pigment. A, Pretreatment appearance. B, Appearance after 1 treatment.

further acknowledged that the current tattoo was created on top of a preexisting tattoo of multiple colors including yellow. Of the 2 recalcitrant tattoos, 1 was similarly described as initially appearing "turquoise," while the other had remaining visible green pigment.

After informed consent was obtained, all patients underwent 2-dimensional photography, and the tattoo was anesthetized with local injection of lidocaine or application of topical compounded 7% tetracaine and 7% lidocaine ointment. Protective eyewear was properly placed on the patients, and appropriate goggles were worn by the treating physician and all staff members present.

All treatments were performed with a novel, 755-nm alexandrite laser, with variable pulse duration of 750 to 900 picoseconds and repetition rate of 5 Hz (Cynosure). Spot sizes ranged from 3.0 to 3.6 mm, with fluence ranging from 2.0 to 2.83 J/cm.² Treatment para-

meters were guided by patient skin type and achievement of clinical end point, namely epidermal whitening, during the initial test spot. The procedure was well tolerated with minimal subsequent downtime, and patients reported an average pain score of 1.08 on a 10-point scale (1 indicating no pain; 10, worst pain). One patient reported blistering, and the remainder noted no more than the formation of crust. Postinflammatory pigmentary alteration was observed in a minority of patients, but on additional follow-up visits, no scarring or residual pigmentary alteration was noted.

Patients returned for follow-up, on average, 1 month after their initial treatment. At this visit, we found that 11 of the 12 treated tattoos had achieved greater than 75% clearance of the blue and/or green pigment after only 1 treatment, with greater than two-thirds of those approaching closer to 100% clearance. The twelfth, a green-only tattoo, required 2 treatments to achieve a

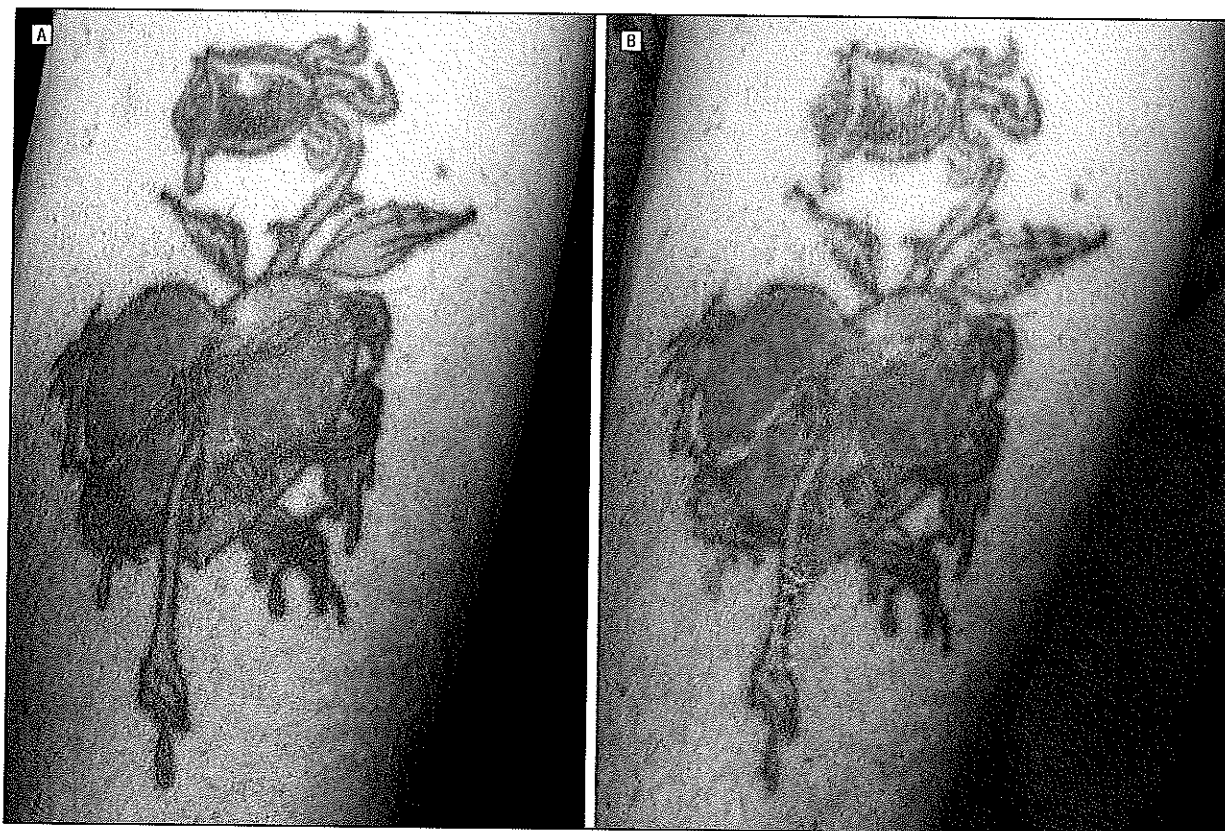


Figure 2. Previously untreated multicolored tattoo, including green pigment. A, Pretreatment appearance. B, Appearance after 1 treatment.

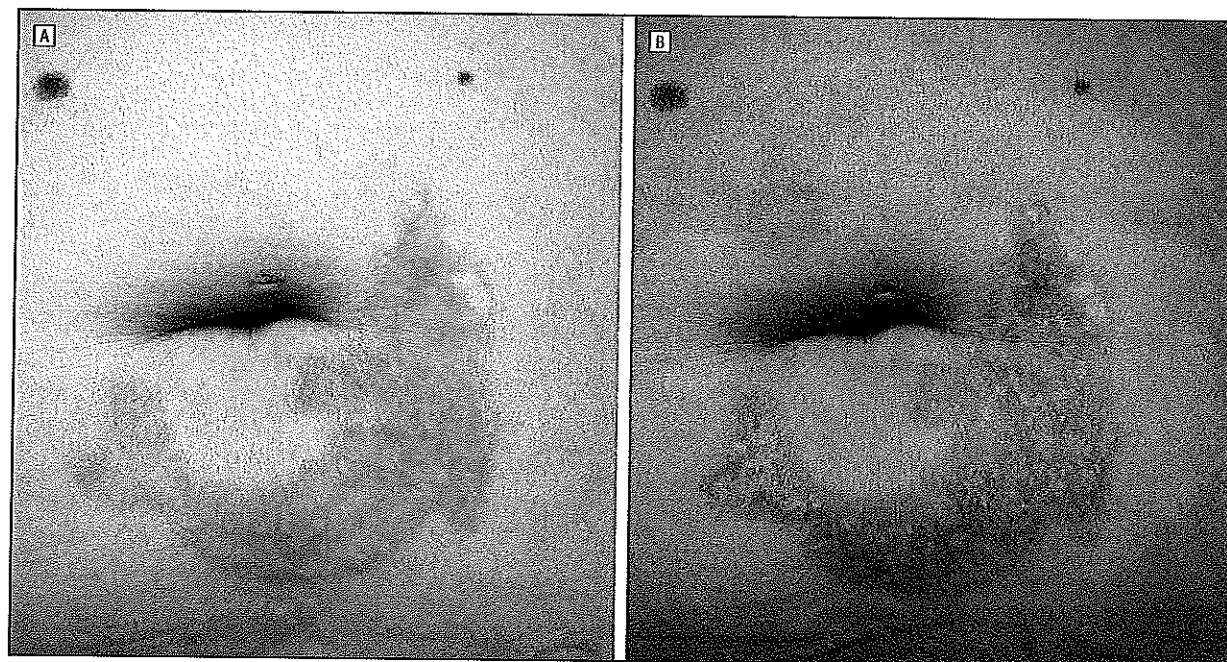


Figure 3. Previously treated but recalcitrant tattoo including "turquoise" pigment. A, Pretreatment appearance. B, Appearance after 1 treatment.

similar rate of clearance. Both tattoos recalcitrant to treatment achieved greater than 75% clearance of the green and "turquoise" pigment after 1 treatment. Of the additional colors noted within the treated tat-

toos, purple similarly demonstrated greater than 75% clearance, but the remainder of the colors showed 25% clearance or less after 1 or 2 treatments (**Figures 1, 2, and 3**).

During initial consultation for tattoo removal, patients are regularly informed that removal will likely take many, often painful sessions, with subsequent blistering, oozing, bruising, and crusting. Furthermore, just as there are many colors individuals can choose from when selecting the design of their tattoo, so too are there many elements and chemical compounds used in the creation of those colors, especially red and green. Because of this, while a particular laser and selected parameters may successfully remove one tattoo of a certain color, they may not work as effectively on another tattoo of the same color.

The age of the tattoo is also important to consider when discussing treatment course and expectations; older tattoos are generally treated more successfully. It is of paramount importance that the physician have proper training in selection of which laser and parameters are most appropriate for the tattoo to be treated. This is often determined based on the laser's wavelength: certain wavelengths have been proven more effective at removing particular colors.^{9,11,12}

The 3 QS lasers regularly used in the removal of tattoos are the ruby (694-nm), neodymium: yttrium, aluminum, garnet (Nd:YAG) (532-nm and 1064-nm), and alexandrite (755-nm). To date, for blue and green tattoos specifically, both the QS ruby and QS 1064-nm Nd:YAG lasers have been shown to be more effective for dark blue pigment.^{11,12} While some researchers have shown the QS alexandrite laser to be the most effective of the 3 for green pigments,¹³ we would not agree with these findings. Instead, it has been our experience that the QS ruby laser is more effective in the removal of both of these colors. However, even with these lasers, success often comes only after a prolonged series of sometimes very painful treatments with an extended recovery time. In our experience, when clearance of green and blue pigment is achieved, it takes an average of 6 to 10, but possibly as many as 20 treatments.

In this report, we present our findings of extremely rapid and successful treatment of 12 green and/or blue tattoos with a novel, picosecond, 755-nm alexandrite laser. All tattoos, those previously untreated as well as those with residual pigment after at least 10 treatments, had between 75% and 100% clearance after only 1 or 2 treatments. We believe this new technology is far more effective in targeting blue and green pigment, with expedited clearance and improved recovery time owing to less collateral injury of surrounding tissue.

Accepted for Publication: February 25, 2012.

Published Online: May 21, 2012. doi:10.1001/archdermatol.2012.901

Correspondence: Jeremy A. Brauer, MD, Laser & Skin Surgery Center of New York, 317 E 34th St, New York, NY 10016 (jbrauer@laserskinsurgery.com).

Author Contributions: Drs Brauer, Reddy, and Geronemus had full access to all of the data in the study and take

responsibility for the integrity of the data and the accuracy of the data analysis. *Study concept and design:* Brauer, Reddy, and Geronemus. *Acquisition of data:* Brauer, Reddy, Anolik, Weiss, Hale, Brightman, Bernstein, and Geronemus. *Analysis and interpretation of data:* Brauer, Reddy, Karen, and Geronemus. *Drafting of the manuscript:* Brauer and Geronemus. *Critical revision of the manuscript for important intellectual content:* Brauer, Reddy, Anolik, Weiss, Karen, Hale, Brightman, Bernstein, and Geronemus. *Statistical analysis:* Brauer and Reddy. *Obtained funding:* Geronemus. *Administrative, technical, and material support:* Geronemus. *Study supervision:* Anolik, Weiss, Karen, Hale, Brightman, Bernstein, and Geronemus.

Financial Disclosure: The treatment device for this research was on loan to us from Cynosure. Dr Geronemus has served as an investigator for Cynosure, Solta, Syneron, Palomar, Cutera, Lithera, Kythera, and L'Oreal; Dr Brightman has served as an investigator for Syneron and Solta; and Dr Weiss has served as an investigator for Lithera. Dr Geronemus has received honoraria from Solta; and Dr Brightman has received honoraria from Syneron, Solta, Candela, Dusa, Lutronics, and Invasix. Dr Weiss has served as a consultant for Lithera; and Dr Hale has served as a consultant for Merck, sanofi-aventis, and Guthy-Renker. Dr Geronemus owns stock or options in Zeltiq.

REFERENCES

- Goldman L, Rockwell RJ, Meyer R, Otten R, Wilson RG, Kitzmiller KW. Laser treatment of tattoos: a preliminary survey of three years' clinical experience. *JAMA*. 1967;201(11):841-844.
- Reid R, Muller S. Tattoo removal by CO laser dermabrasion. *Plast Reconstr Surg*. 1980;65(6):717-728.
- Apfelberg DB, Maser MR, Lash H. Argon laser treatment of decorative tattoos. *Br J Plast Surg*. 1979;32(2):141-144.
- Anderson RR, Parrish JA. Microvasculature can be selectively damaged using dye lasers: a basic theory and experimental evidence in human skin. *Lasers Surg Med*. 1981;1(3):263-276.
- Anderson RR, Parrish JA. Selective photothermolysis: precise microsurgery by selective absorption of pulsed radiation. *Science*. 1983;220(4596):524-527.
- Reid WH, McLeod PJ, Ritchie A, Ferguson-Pell M. Q-switched ruby laser treatment of black tattoos. *Br J Plast Surg*. 1983;36(4):455-459.
- Graber E, Iyengar V, Rohrer T, et al. Laser treatment of tattoos and pigmented lesions. In: Robinson JK, Hanke CW, Siegel DM, Fratila A, eds. *Surgery of the Skin: Procedural Dermatology*. 2nd ed. China: Mosby; 2010:537-548.
- Ara G, Anderson RR, Mandel KG, Ottosen M, Oseroff AR. Irradiation of pigmented melanoma cells with high intensity pulsed radiation generates acoustic waves and kills cells. *Lasers Surg Med*. 1990;10(1):52-59.
- Kent KM, Graber EM. Laser tattoo removal: a review. *Dermatol Surg*. 2012;38(1):1-13.
- Taylor CR, Anderson RR, Gange RW, Michaud NA, Flotte TJ. Light and electron microscopic analysis of tattoos treated by Q-switched ruby laser. *J Invest Dermatol*. 1991;97(1):131-136.
- Leuenberger ML, Mulas MW, Hata TR, Goldman MP, Fitzpatrick RE, Grevelink JM. Comparison of the Q-switched alexandrite, Nd:YAG, and ruby lasers in treating blue-black tattoos. *Dermatol Surg*. 1999;25(1):10-14.
- Lin T, Jia G, Rong H, Li J, Zhou Z. Comparison of a single treatment with Q-switched ruby laser and Q-switched Nd:YAG laser in removing black-blue Chinese tattoos. *J Cosmet Laser Ther*. 2009;11(4):236-239.
- Zelickson BD, Mehregan DA, Zarrin AA, et al. Clinical, histologic, and ultrastructural evaluation of tattoos treated with three laser systems. *Lasers Surg Med*. 1994;15(4):364-372.